



Thyrotoxicosis in Partial Mola Hidatidosa

I Gusti Agung Wedanta Mahadewi¹, Arya Baruna Purwa Sunu², Suryantha Adisastra³

¹Affiliation Klungkung Regional General Hospital, Email: dantamahadewi@ymail.com

²Affiliation of Internal Medicine Medical Staff of Klungkung Regional General Hospital, Email: barunaarya@gmail.com

³Affiliation of Obstetrics and Gynecology Medical Staff of Klungkung Regional General Hospital, Email: suryantha.adisastra@gmail.com

Corresponding Author: Gusti Agung Wedanta Mahadewi¹

Abstract: Thyrotoxicosis is a clinical condition associated with excessive thyroid hormone levels. Symptoms can range from asymptomatic to life-threatening due to thyroid storm. Thyrotoxicosis in hydatidiform moles is a rare condition but has a high mortality rate, so etiological studies are still needed for optimal management. **Case Report:** Patient Mrs. T, 25 years old Hindu, Balinese, 12 weeks pregnant (Gravida 1 Para 0 abortion 0), came to the obstetrics ER on September 24, 2023 with complaints of discharge from the birth canal since the morning, nausea (+), often shaking, easily tired and often sweaty. physical examination obtained blood pressure 100/60mmHg, pulse 78x/min, respiratory rate 20x/min, axillary temperature 36.80C oxygen saturation 99%. From obstetric examination, fundus uteri height ½ center, vaginal toucher vulva vagina within normal limits, portiono (-) fluxus (+), laboratory examination obtained HCG 387,392.8 mIU/m, FT4 31.05 pmol/L (N: 9-22), TSH <0.01 uIU/mL (N: 0.4-4.2) ultrasound results describe honey comb appearance and histopathology results describe partial mola. Evacuation by curettage was performed, resulting in reduced serum β -hCG levels and reduced thyroid hormone levels. **Discussion:** The patient was diagnosed with partial hydatidiform mole and thyrotoxicosis. Hydatidiform moles can cause thyrotoxicosis. This condition is caused by the structure of β - hCG which resembles TSH so that it can activate TSH receptors. After evacuation of hydatidiform moles, normal TSH and FT4 levels will be obtained. **Conclusion:** The female patient with thyrotoxicosis due to hydatidiform moles had the moles evacuated, resulting in normal thyroid hormone levels.

Keyword: β - hCG, hydatidiform mole, thyrotoxicosis, TSH

INTRODUCTION

Thyrotoxicosis is a clinical condition associated with excessive thyroid hormone levels, generally due to high thyroid hormone circulation. Symptoms can range from asymptomatic or subclinical to life-threatening due to thyroid storm.

Subclinical thyrotoxicosis is a condition that affects 10% of the world's population. Where treatment should be done in patients with serum TSH levels $<0.1\text{U/L}$. The prevalence of thyrotoxicosis cases in the US is 1.2% including 0.5% overt thyrotoxicosis and 0.7% subclinical thyrotoxicosis. In Indonesia, the exact prevalence of thyrotoxicosis is unknown but the prevalence of hyperthyroidism is 0.4% and in the United States, the prevalence of hyperthyroidism is 1.2% and in Europe 0.8%. Hyperthyroidism increases with age and is more common in women. The ratio between women and men is 8:1 where manifestations will appear in the third and fourth decades.

The causes of thyrotoxicosis can be divided into 2 namely endogenous and exogenous. The most common endogenous causes are Grave's Disease, toxic multinodular goiter, toxic adenoma, hyperthyroidism mediated by $\beta\text{-HCG}$ While the cause of exogenous thyrotoxicosis is excessive therapy with levothyroxine.

Gestational trophoblastic disease (PTG) is a trophoblastic lesion characterized by hydropic swelling of the chorionic villi and trophoblastic proliferation. The incidence of hydatidiform mole in the United States is 1% of 1,000 - 2,000 pregnancies and malignant transformation occurs in 6% - 19% of them. The prevalence of hyperthyroidism during molar hydatidiform pregnancy is 7%. Thyroid crisis occurs in 2% - 4% of pregnant women with hyperthyroidism and mortality is 20% - 30%.

Thyrotoxication in hydatidiform mole is a rare condition but has a high mortality rate because it causes various complications such as acute heart failure or postoperative thyroid crisis.

Case Report

Patient on behalf of Mrs. T, 25 years old Hindu religion, Balinese ethnicity 12 weeks pregnant (Gravida 1 Para 0 Abortus 0), came to the obstetrics ER (VK ER) Klungkung Hospital on September 24, 2023 with complaints of discharge of spots from the birth canal since the morning, nausea (+) vomiting (-) often shaking, easily tired and often remembering abdominal pain denied, fever denied, tightness and palpitations also denied. The patient last menstruated 3 months ago, this pregnancy is the first pregnancy where the patient has no history of systemic disease, drug allergies are also denied. Then an abdominal ultrasound was performed and found partial hydatidiform mole and the patient was then referred for hospitalization and planned for dilatation and curettage.

On vital sign examination, the patient was found to have compos mentis consciousness (E4V5M6) with moderate general condition. Blood pressure 100/60mmHg with pulse 78x/min strong lift and regular, respiratory rate 20x/min and axillary temperature obtained 36.80C and oxygen saturation 99%. From obstetric examination obtained fundus uteri height palpable $\frac{1}{2}$ center, , from vaginal toucher vulva vagina obtained portiono (-) cervical dilatation (-), flux (+).

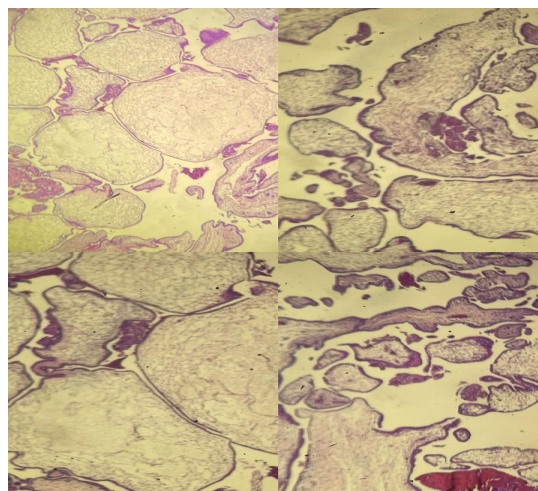


Figure 1. Partial histopathologic features of moles

At the laboratory examination the results were obtained, Hb value 12.4g/dL (N: 10.8-16.5), leukocytes 11,350/uL (N: 3,500-10,000), Hematocrit 37.7% (N: 35-55), platelets 245,000/uL (N: 145,000-450,000), GDS: 77mg/dl (N: 80-200), \square HCG 387,392.8 mIU/m, FT4 31.05 pmol/L (N: 9-22), TSH <0.01 uIU/mL (N: 0.4-4.2). The patient was then subjected to uterine ultrasonography (USG) examination and found a picture with sufficient blood content, gestational sac appearance, intrauterine CRL 4.99 cm according to 11W5D, FHB (-) intrauterine hypohyperechoic appearance, honey comb appearance, partial hydatidiform mole impression Adnexa mass (-), Free fluid (-).

The patient was co-treated between the obgyn and internal medicine departments with a diagnosis of thyrotoxicosis due to partial hydatidiform mole. For handling in the obgyn department with a diagnosis of partial hydatidiform mole, dilatation and curettage were performed on September 25, 2023 and then treated in the ICU for one day and from anesthesia given NaCl 0.9% fluid therapy 21 tpm, omeprazole 2x40mg IV, Ibuprofen 3x400mg IV, paracetamol 4x1gr IV, and ondancetron 3x4mg IV. For therapy from the obgyn department after dilated curettage, amoxicillin 3x500mg PO and mefenamic acid 3x500mg PO, methylergometrine 3x1 tab. For therapy from the internal medicine department before the patient undergoes surgery, thyrozol 1x20mg is given, and after the operation thyrozol is continued at a dose of 1x20mg.

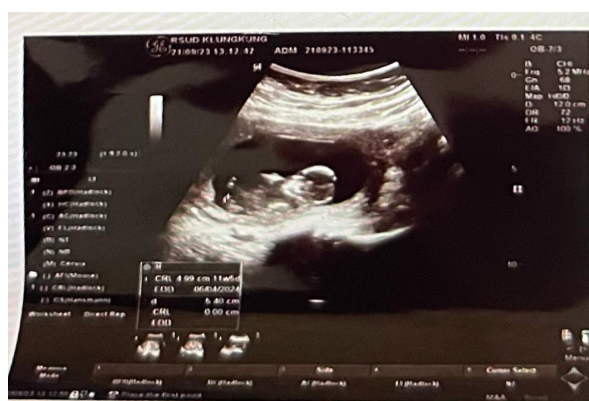

Figure 2. Ultrasound partial view of hydatidiform mole

The patient's post-operative condition is stable with the results of a physical examination within normal limits and vital signs within normal limits, namely blood pressure 115/68mmHg, pulse 78x/min, respiratory rate 12 x/min axillary temperature 36.0C and saturation 99%. Post op the patient received ICU care for one day for close observation and then the patient was transferred to the general care room and discharged on the 4th day and advised to re-control the condition to the obgyn and internal medicine poly.

For discharge medication, the patient was given amoxicillin 3x500mg PO, mefenamic acid 3x500mg PO, methylergomrtrin 1x1tab, and thyrozole 1x10mg. On October 2, the patient made a control at the obstetrics clinic and an examination was carried out β HCG which was 2,049.5 and the patient's condition was in good condition then on October 9, a re-evaluation was carried out for the patient's β HCG and obtained a decrease of 504.7. On October 11, the patient controlled at the internal medicine clinic and performed an FT4 examination and found a decrease of 22.5 and performed a thyroid ultrasound examination and found normal results and the patient had no complaints.

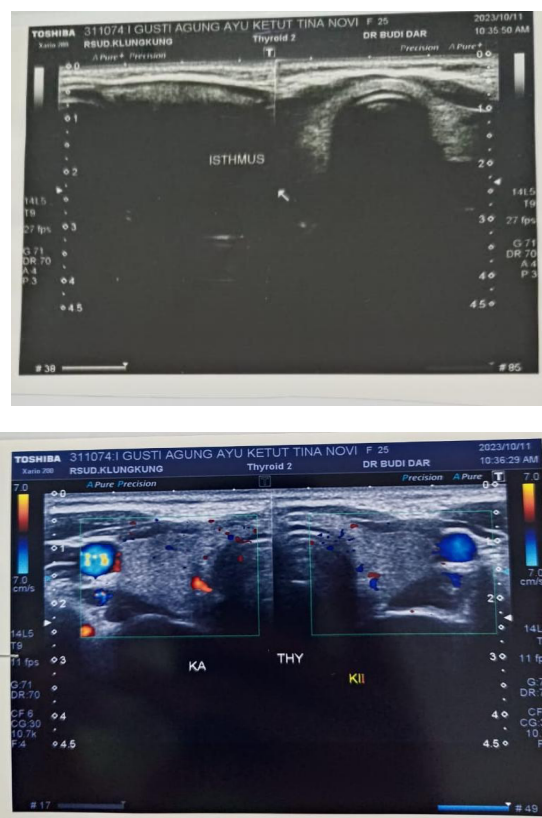


Figure 3. USG post curettage thyroid gland

RESULTS AND DISCUSSION

Hydatidiform mole is a trophoblastic lesion characterized by hydrophilic swelling of the chorionic villi and trophoblastic proliferation generally characterized by high levels of β -HCG. Hydatidiform mole is one of the rare diseases, but if not detected and treated as soon as possible, it will develop into a trophoblastic cell malignancy, which occurs in 15%-20% of women with complete hydatidiform mole and 2%-3% in partial hydatidiform mole. Malignant hydatidiform mole occurs if metastasis and invasion penetrate and damage the myometrium, this condition can occur in invasive mole.

There are several conditions that etiologize this disease including various combinations of environmental and genetic factors. Age is one of the influential factors where moles usually appear in young patients (<16 years old) and those >45 years old. In addition to age, spacing between pregnancies, previous history of abortion and moles and socio-economics.

In the above case, the patient was a 25-year-old woman who was pregnant with her first child, and her previous history of abortion and molar was denied. The patient works as a casual worker with the last education of junior high school. So that the risk factor that is most likely to be the etiology in the patient is the patient's socio-economy so that the knowledge of examination and ANC in the patient is still very common. In the anamnesis, it was also mentioned that the patient's husband was an active smoker where lifestyles such as smoking and alcoholism will increase the incidence of hydatidiform mole. The patient's mother was also said to have experienced grape pregnancy. Genetic factors that are closely related to hydatidiform mole are chromosome 19q13 and most commonly chromosome 11p dominantly expressed from the maternal allele. The allele is familial and inherited in an autosomal recessive manner.

The classification of hydatidiform moles based on the International Federation of Gynecology and Obstetrics (FIGO) is divided into complete hydatidiform moles and partial hydatidiform moles (benign PTG), and invasive hydatidiform moles (malignant PTG).

Complete hydatidiform mole is found in abnormal pregnancies without embryos, with hydrophic swelling of the placental villi and often trophoblastic hyperplasia in both layers. Complete hydatidiform mole contains only paternal DNA so it is androgenetic without any fetal tissue. Partial hydatidiform moles are triploids that contain two sets of paternal chromosomes and one set of maternal chromosomes, but triploids that have two sets of maternal chromosomes will not be partial hydatidiform moles.

To diagnose hydatidiform mole, ultrasonography (USG), β -hCG level testing, and chorionic villus, amniocentesis, or fetal blood sampling are performed. On ultrasound examination, high-risk hydatidiform mole can be accurately diagnosed in the first week of pregnancy when β -hCG examination is difficult to diagnose. On ultrasound examination, for complete hydatidiform mole, a snowstorm picture will be found. Whereas patients with partial hydatidiform mole are often diagnosed with missed abortion and there is a fetal picture, but lutein cysts are rarely seen. Histopathologic examination of the conception sample is the gold standard examination of hydatidiform mole. It can also be used to determine the patient's prognosis. β -HCG is a hormone produced during pregnancy by syncytiotrophoblast cells. In normal pregnancy, β -hCG will increase during week 2. In complete hydatidiform moles, β -hCG levels can reach more than 100,000 IU/L. Meanwhile, in partial hydatidiform mole, the β -hCG level is generally the same as a normal pregnancy or exceeds it. The β -hCG test can also be used to diagnose various gestational trophoblastic diseases post hydatidiform mole that suggest malignancy.

In the patient, an ultrasound examination was performed where it was found from the results of a partial hydatidiform mole ultrasound and a β -HCG examination was performed and the results were 387,392.8 mIU/m, although the β -HCG levels impressed complete mola, the gold standard examination was carried out where an anatomical pathology examination of the curette specimen was performed and a partial hydatidiform mola picture was obtained. Where the gold standard examination for hydatidiform moles is from histopathology.

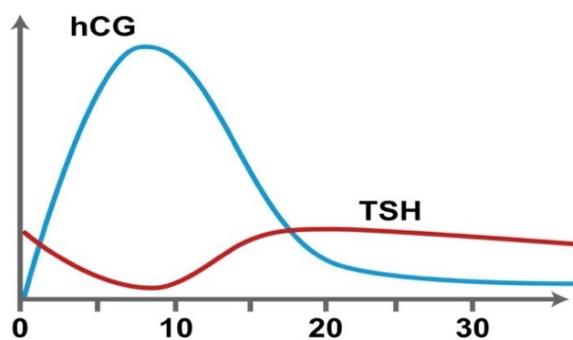


Figure 4. Graph of hCG hormone against TSH

HCG is a specific tumor marker glycoprotein hormone in trophoblastic diseases. Where structural analogies between HCG and TSH cause cross-reactivity with their receptors. Homologies in the HCG and TSH molecules, as well as in their receptors, are responsible for the cross-reactivity of HCG with the TSH receptor.¹³ It is estimated that for every 10,000 IU/L increase in serum β -HCG, FT4 increases by 0.1 ng/dL, and TSH decreases by 0.1 mIU/mL. And molecular variants of β -HCG found in molar pregnancies have increased thyrotropic potential. HCG can also activate TSH receptors when overproduced and induce thyrotoxicosis. More than 40% of patients with β -HCG > 50,000 mIU/ml are biochemically hyperthyroid. Due to the similar receptors on HCG and TSH, HCG acts directly on the TSH receptors located on the thyroid gland and causes an increase in T3 and T4 levels and a decrease in TSH.¹⁴ In addition to the examination of β -HCG, FT4 and TSH to determine the condition of hypermetabolism can be done Wayne index calculation whose results can support laboratory

results. Patients with a score of more than 20 are said to have symptoms of thyrotoxicosis. However, patients with thyrotoxicosis on laboratory results may produce a Wayne score below 20 points because in some cases, thyrotoxicosis causes insignificant subjective symptoms. In this case, the patient had a score of 10 based on the calculation of the Wayne index but because the laboratory results found FT3 and FT4 significantly increased and very low TSH levels of $<0.005 \mu\text{IU/ml}$, the suspicion of thyrotoxicosis could be established.

The definitive therapy in hydatidiform mole either partial or complete is evacuation of mole tissue. Evacuation and curettage are performed with ultrasound guidance. Mola evacuation is performed when the patient's hemodynamics are stable. Because mole evacuation accompanied by thyrotoxicosis without suppressing thyroid hormone levels will trigger a thyroid storm.

Thyroid storm is a life-threatening condition in thyrotoxicosis. There are even cases of thyroid storm occurring after evacuation of mild hydatidiform mole. This condition is due to inflammation during the evacuation process causing an increase in metabolism, triggering the production of more thyroid hormones. Excess hormones in circulation stimulate increased activity in organ receptors, which can lead to more organ dysfunction.

Table 1 Wayne Index

Gejala	Skor	Tanda-tanda	Skor	
			Ada	Tidak
Sesak nafas	1	Pembesaran tiroid	3	-3
Palpitasi	2	Bruit pada tiroid	2	-2
Mudah lelah	2	Eksopthalmus	2	0
Senang hawa panas	-5	Retraksi palpebra	2	0
Senang hawa dingin	5	Palpebra terlambat	1	0
Keringat berlebihan	3	Gerak hiperkinetik	4	-2
Gugup	2	Telapak tangan kering	2	-2
Nafsu makan bertambah	1	Telapak tangan basah	1	-1
Nafsu makan berkurang	-3	Nadi $< 80/\text{menit}$	-3	0
Berat badan naik	-3	Nadi $> 90/\text{menit}$	3	0
Berat badan turun	3	Fibrasi atrial	4	0

In this patient, definitive therapy was performed in the form of curettage. Where before the action is taken so that the patient's hemodynamics are stable and prevent thyroid storm during the action and post-action is given therapy to suppress thyroid levels, namely thyrozol 1x20mg. this patient was also observed for 1 day in the ICU because of the high risk of post-curettage thyroid storm.

Thyrozol with thiamazole content is an antithyroid drug of the thionamides group. Its main mechanism of action is to block the production of thyroid hormones in the thyroid gland and interfere with the iodination step of tyrosine residues in thyroglobulin, which is mediated by the enzyme thyroid peroxidase, thus preventing the synthesis of thyroxine (T4) and triiodothyronine (T3). Methimazole or thiamazole is given 20-40 mg/day and can also be given a single daily dose if the patient has reached or is approaching an euthyroid state. This patient was given thiamazole group therapy because of its higher efficacy compared to PTU in terms of reducing T3, T4, FT3 and FT4 levels, reducing the risk of liver damage and increasing TSH levels.

Evaluation of post curettage patients with hydatidiform mole is classified into whether the patient is low or high risk. As for the high risk, conditions such as $\beta\text{-HCG} \geq 100,000\text{IU/ml}$ or uterine size less than gestational age or ovarian cysts less than 6cm are found. further post-action follow-up supervision is carried out on patients with the aim of whether the involution process is normal and early detection of malignancy. Follow-up supervision is carried out for

1 year where in high-risk moles, weekly checks are carried out in the first 3 months, examining the patient's condition and complaints and looking at signs of subinvolution. The second 3 months are checked every 1 month and the last 6 months every 2 months.

In this patient, because she was classified as a high-risk molar, the β -HCG level was re-examined 7 days and 14 days post curettage and found a decrease in β -HCG levels in the first week of 2045.5 and in the second week of 504.7 and there were no complaints in the patient. At the time of control in the internal medicine department, thyroid levels and thyroid ultrasound were re-examined and as expected, thyrotoxicosis was cured by treatment and normalization of β -HCG levels. Therefore, thyroid medication in this patient could be discontinued.

CONCLUSION

A 25-year-old female patient with thyrotoxicosis due to hydatidiform mole has undergone mole evacuation by curettage, resulting in normal thyroid hormone levels of both TSH and FT4.

Treatment in cases like this should focus on etiologic management, and it is mandatory to check the thyroid hormone status of the patient before mola evacuation. Normal thyroid levels should be achieved immediately before molar evacuation to prevent thyroid storm effect which is a life-threatening condition.

REFERENCES

- Blick, C., et al. 2023. "Thyrotoxicosis". *National Library of Medicine*. National Center for Biotechnology Information
- Carle, A. et al. 2017. "Penatalaksanaan Penyakit Endokrin: Tirotoksikosis Subklinis: Prevalensi, Penyebab dan Pilihan Terapi". *European Society of Endocrinology*. 176(6): 325-337
- Devereaux D, Tewelde SZ. "Hipertiroidisme dan tirotoksikosis". *Emerg Med Clin Utara Am*. Mei 2014;32(2): 277-92)
- The Indonesian Society of Endocrinology Task Force on Thyroid Diseases. Indonesian Clinical Practice Guidelines for Hipertiroidisme. Vol. 27 No. 2012. ISSN 0857-1074 ,
- Bartalena L, Fatourech V. Manifestasi ekstratiroidal penyakit Graves: pembaruan tahun 2014. *JInvestasi Endokrinol*. Agustus 2014; 37 (8):691-700. [PubMed]
- Mayura, IGN., Saraswati, MR. 2016. "Penyakit Tropoblastik Gestasional dan Krisis Tiroid". *Medicina*: 47(3): 47-51
- See HT, Freedman RS, Kudelka AP, Kavanagh JJ. 2006. "Gestational Trophoblastic Disease. Gynecologic Cancer". *Anderson Cancer Care Series*; 5:226-43)
- Deep JP, Sedhai LB, Napit J, Pariar J. 2013. "Gestasional Trophoblastic Disease". *JCMC*;3(4): 4-11)
- Kusuma A, Pramono B. "Karakteristik Mola Hidatidosa Di Rsup Dr. Kariadi Semarang". *J Kedokt Diponegoro*. 2017;6(2):319-327.
- Septiyaningsih D. "Faktor-faktor ibu yang mempengaruhi kejadian mola hidatidosa". *J Kesehat Al-Irsyad*. 2016;9(2):17-24.)
- Wagey FW, Lengkong RA. "Profil penderita mola hidatidosa di RSUP Prof. Dr . R . D . Kandou". 2016;4.
- Olivia FC, Kedokteran F, Lampung U. Seorang Wanita 30 Tahun Dengan Mola Hidatidosa Komplet A 30 Years Old Woman with Complete Hydatidiform Mole. 2016;5
- Nugraha GBA, Samodro P. 2019. "Case study: Thyrotoxicosis on women with complete hydatidiform molar pregnancy." *J Kedoktera dan Kesehatan Indones*; 10(3):292-7.
- XiongY, MaY, WuL, LuoD, BhatS, Maletkovic J. *Case Report: A Hydatidiform Mole Can Cause Severe Gestational Hyperthyroidism*. *Clin Thyroid*. 2013;29825(8):16913-7.

- Idrose AM. *Acute and emergency care for thyrotoxicosis and thyroid storm*. *Acute Med Surg*.2015;2(3):147–57
- Virmani S, Srinivas SB, Bhat R, Rao R, Kudva R. *Transient thyrotoxicosis in molar pregnancy*. *J Clin Diagnostic Res*.2017;11(7):QD01- 2).
- Abraham P, Acharya S. Pilihan Pengobatan saat ini dan yang muncul untuk hipertiroidisme graves. *Ada manajer Risiko Clin*. 02 Februari 2010; 6:29-40
- Tan, Shuang et all. 2021. Studi Meta-Analisis The efficiency and safety of methimazole and propylthiouracil in hyperthyroidism. *Baltimore medicine*
- Bag/SMF Obstetrik dan Ginekologi Fakultas Kedokteran Universitas Udayana Rumah Sakit Umum Pusat Sanglah Denpasar. Panduan Paktrek Klinik Obstetrik dan Ginekologi. Denpasar: 2015